

Case report

Macular oedema following rituximab infusion in two patients with Wegener's granulomatosis

G. Bussone¹, G. Kaswin², M. de Menthon¹, E. Delair², A.P. Brézin², L. Guillevin¹

Université Paris Descartes,

¹Service de Médecine Interne,

²Service d'Ophthalmologie, Hôpital Cochin, Assistance Publique – Hôpitaux de Paris, Paris, France.

Guillaume Bussone, MD

Godefroy Kaswin, MD

Mathilde de Menthon, MD, PhD

Emmanuelle Delair, MD

Antoine P. Brézin, MD, PhD

Loïc Guillevin, MD

Please address correspondence to:

Dr Loïc Guillevin,

Service de Médecine Interne,

Hôpital Cochin,

27 rue du Faubourg Saint-Jacques,

75679 Paris Cedex 14, France.

E-mail: loic.guillevin@cch.aphp.fr

Received on November 17, 2009; accepted in revised form on February 16, 2010

Clin Exp Rheumatol 2010; 28 (Suppl. 57): S90-S92.

© Copyright CLINICAL AND

EXPERIMENTAL RHEUMATOLOGY 2010.

Key words: Wegener's granulomatosis, scleritis, rituximab, cystoid macular oedema.

ABSTRACT

Rituximab, a monoclonal antibody now widely used to treat autoimmune diseases, has been reported to be effective against refractory Wegener's granulomatosis and its ophthalmic involvement. Herein, we report on 2 patients with refractory Wegener's granulomatosis and scleritis in whom cystoid macular oedema occurred several weeks after rituximab infusions. Notably, scleritis had already resolved when macular oedema was diagnosed. One patient's macular oedema was successfully treated with a subtenon injection of triamcinolone but recurred soon after she received a second cycle of rituximab as maintenance therapy. To our knowledge, to date no ophthalmic side effect has been reported after rituximab administration. The short time between each rituximab infusion and the onset of cystoid macular oedema strongly suggests a causal link.

Introduction

Wegener's granulomatosis (WG) is a systemic vasculitis responsible, in about 50% of the patients (1), for ocular manifestations, which are usually associated with other visceral symptoms affecting, e.g. lungs and/or kidneys. Immunosuppressants are the cornerstone of treatment, particularly the combination of high-dose corticosteroids and intravenous cyclophosphamide. But treatment of refractory ocular manifestations during WG remains poorly established.

Rituximab, a monoclonal antibody directed against the CD20 antigen expressed on the surface of B lymphocytes, is widely used to treat autoimmune diseases (2). Rituximab has been shown to be effective against refractory WG (3-6) and was recently described to have efficacy in patients with

refractory ophthalmic manifestations of WG (7-9), in contrast to an earlier publication (10).

Rituximab side effects include fever, shivers or rashes during infusions, and enhanced susceptibility to infections, but cystoid macular oedema has never been reported. We describe 2 patients with refractory WG and scleritis in whom clinical responses were obtained after rituximab infusions but were followed by cystoid macular oedema.

Case reports

Case 1

A 64-year-old woman with no remarkable medical history consulted in 2003 for a red and painful right eye leading to the diagnosis of nodular scleritis. Local treatment with corticosteroid drops was started but had no effect. Computed tomography (CT) revealed pulmonary infiltrates and paranasal sinusitis; the patient's serology was positive for antiproteinase-3 antineutrophil cytoplasm antibodies (ANCA). Lung biopsy showed epithelioid granulomas without vasculitis and cultures of it were negative for mycobacteria. WG was diagnosed. Corticosteroids (1 mg/kg/d) and 6 intravenous pulses of cyclophosphamide (600 mg/m²) achieved remission and azathioprine (2 mg/kg/d) was prescribed as maintenance therapy but was stopped because of hepatocytolysis. Methotrexate (20 mg/wk) was prescribed but stopped because of digestive intolerance, relayed by mycophenolate mofetil (2 g/d).

In September 2006, the patient's WG relapsed, with asthenia, scleritis of the right eye and more severe pulmonary infiltrates reappeared. The scleritis responded to 6 more intravenous pulses of cyclophosphamide (600 mg/m²), but pulmonary lesions persisted. Rituximab was then infused twice in April

Competing interests: none declared.

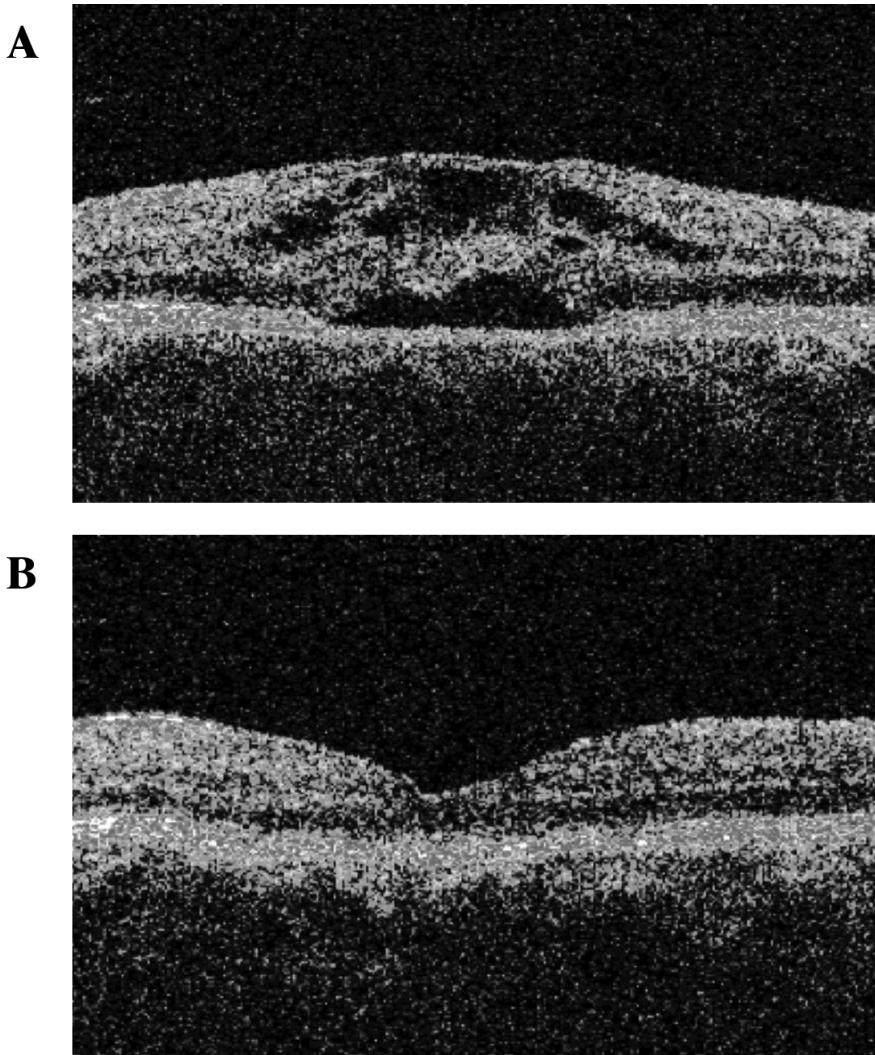


Fig. 1. Optical coherence tomography (OCT) of patient 1's right macula. A. One month after rituximab infusions, OCT revealed cystoid macular oedema with central foveal thickness of $469 \pm 68 \mu\text{m}$. B. Two months after triamcinolone injection, the foveal profile was normal and the central foveal thickness was $160 \pm 21 \mu\text{m}$.

2007 (1000 mg on days 1 and 15). One month later, she complained of vision loss in her right eye. Ophthalmologic examination revealed a best-corrected decimal visual acuity (BCVA) of 0.6, caused by cystoid macular oedema without scleritis (Fig. 1A). The left eye was normal. Corticosteroids (0.5 mg/kg/d) and methotrexate (12.5 mg/wk) were started for possible WG relapse. Methotrexate was stopped 6 months later because of lack of efficacy. Eight months later, the patient was treated with a subtenon injection of triamcinolone (40 mg). Two months later, her BCVA increased to 1.0 and macular oedema had receded (Fig. 1B). In November 2008, the patient received another rituximab infusion (375 mg/m^2) as maintenance

therapy for WG. In December 2008, her right eye vision was again blurry, her BCVA dropped to 0.3, and macular oedema was again diagnosed. The left eye remained normal. In February 2009, the patient was treated again with a subtenon injection of triamcinolone. Two months later, BCVA increased to 0.6 and the foveal profile was normal, without macular oedema.

Case 2

A 39-year-old woman with chronic sinusitis and scabby rhinitis was seen in 2003. In 2006, she developed left serous otitis. In May 2007, a chest CT scan revealed pulmonary nodules, 1 of which was excavated. The patient's serology was positive for antiprotein-

ase-3 ANCA, and WG was diagnosed. The patient received corticosteroids (1 mg/kg/d) and 9 intravenous pulses of cyclophosphamide (600 mg/m^2). In December 2007, azathioprine (2 mg/kg/d) was started as maintenance therapy. However, WG relapsed 1 month later, with rhinitis, new pulmonary nodules and anterior scleritis of the left eye. Visual acuity and fundus examination were normal. Corticosteroids were increased to 15 mg/d, and oral cyclophosphamide (100 mg/d) was started but rapidly stopped because of cytopenia. Despite azathioprine (3 mg/kg/d), scleritis remained uncontrolled. Rituximab ($375 \text{ mg/m}^2/\text{wk}$ for 4 weeks) was started in October 2008 and azathioprine was tapered to 100 mg/d. Scleritis regressed under rituximab but the patient consulted again in December 2008 for loss of vision in the left eye; her BCVA was 0.2 and cystoid macular oedema was diagnosed. As scleral thinning was observed after resolution of scleritis, intra- or peri-ocular injections were judged to be contraindicated. Therefore, the patient was treated with methylprednisolone infusions (500 mg, three consecutive days). In June 2009, under corticosteroids and azathioprine, BCVA increased to 0.5 but persistent macular oedema was observed. In October, BCVA increased to 1.0 and the foveal profile was normal, without macular oedema.

Discussion

Ophthalmic manifestations of WG usually require immunosuppressants, such as high-dose corticosteroids and intravenous cyclophosphamide. Taylor *et al.* recently reported rituximab efficacy against refractory ophthalmic WG (7). Responses were obtained in 10 patients including 3 with refractory scleritis, 4 with orbital granulomas and 3 with both. No major side effects were reported, especially no cystoid macular oedema. Another patient with relapsing scleritis associated with limited WG was successfully treated with rituximab (8). These reports contradicted previous observations of rituximab failure in patients with WG and scleritis (10). But macular oedema was never reported. Moreover, no severe ophthalmic side effect was reported after rituximab

infusions into patients with lymphoma or autoimmune disease. Posterior scleritis can cause macular oedema (11). Both patients had histories of anterior scleritis but no sign of scleral inflammation was observed when macular oedemas were detected. No other medication had been added between rituximab infusion and macular oedema onset. Both patients' WG responded to rituximab, but macular oedema occurred rapidly after the last rituximab infusion. Moreover, in patient 1, macular oedema recurred soon after the second rituximab cycle, which was prescribed as maintenance therapy for WG in complete remission. The pathophysiology of macular oedema after rituximab infusion is unclear. However, the timeline between rituximab infusion and macular oedema, especially its recurrence following rituximab reinfusion strongly suggests a causal link. Paradoxical intraocular inflammation has been observed after injection of etanercept. Indeed, atypically severe uveitis was reported in a patient with ankylosing spondylitis treated with etanercept, despite the biologic being extremely effective against

articular manifestations (12). Although rituximab was successfully used to treat an isolated case of intraocular inflammation (13), physicians should be aware of the possible occurrence of paradoxical macular oedema with this agent.

References

1. PAKROU N, SELVA D, LEIBOVITCH I: Wegener's granulomatosis: ophthalmic manifestations and management. *Semin Arthritis Rheum* 2006; 35: 284-92.
2. BUSSONE G, HACHULLA E, SIBILIA J *et al.*: [Treatment of systemic autoimmune and inflammatory diseases with rituximab]. *Presse Med* 2009; 38: 808-23.
3. SEO P, SPECKS U, KEOGH KA: Efficacy of rituximab in limited Wegener's granulomatosis with refractory granulomatous manifestations. *J Rheumatol* 2008; 35: 2017-23.
4. SANCHEZ-CANO D, CALLEJAS-RUBIO JL, ORTEGO-CENTENO N: Effect of rituximab on refractory Wegener granulomatosis with predominant granulomatous disease. *J Clin Rheumatol* 2008; 14: 92-3.
5. ROCCATELLO D, BALDOVINO S, ALPA M *et al.*: Effects of anti-CD20 monoclonal antibody as a rescue treatment for ANCA-associated idiopathic systemic vasculitis with or without overt renal involvement. *Clin Exp Rheumatol* 2008; 26 (Suppl. 49): S67-71.
6. BRIHAYE B, AOUBA A, PAGNOUX C, COHEN P, LACASSIN F, GUILLEVIN L: Adjunction of rituximab to steroids and immuno-suppressants for refractory/relapsing Wegener's granulomatosis: a study on 8 patients. *Clin Exp Rheumatol* 2007; 25 (Suppl. 44): S23-7.
7. TAYLOR SR, SALAMA AD, JOSHI L, PUSEY CD, LIGHTMAN SL: Rituximab is effective in the treatment of refractory ophthalmic Wegener's granulomatosis. *Arthritis Rheum* 2009; 60: 1540-7.
8. ONAL S, KAZOKOGLU H, KOC A, YAVUZ S: Rituximab for remission induction in a patient with relapsing necrotizing scleritis associated with limited Wegener's granulomatosis. *Ocul Immunol Inflamm* 2008; 16: 230-2.
9. MARTINEZ DEL PERO M, CHAUDHRY A, JONES RB, SIVASOTHY P, JANI P, JAYNE D: B-cell depletion with rituximab for refractory head and neck Wegener's granulomatosis: a cohort study. *Clin Otolaryngol* 2009; 34: 328-35.
10. ARIES PM, HELLMICH B, VOSWINKEL J *et al.*: Lack of efficacy of rituximab in Wegener's granulomatosis with refractory granulomatous manifestations. *Ann Rheum Dis* 2006; 65: 853-8.
11. JABS DA, MUDUN A, DUNN JP, MARSH MJ: Episcleritis and scleritis: clinical features and treatment results. *Am J Ophthalmol* 2000; 130: 469-76.
12. MONNET D, MOACHON L, DOUGADOS M, BREZIN AP: Severe uveitis in an HLA-B27-positive patient with ankylosing spondylitis. *Nat Clin Pract Rheumatol* 2006; 2: 393-7.
13. TAPPEINER C, HEINZ C, SPECKER C, HEILIGENHAUS A: Rituximab as a treatment option for refractory endogenous anterior uveitis. *Ophthalmic Res* 2007; 39: 184-6.